

Research Article

Dietary effects of three genera of cyanobacteria on histopathology and antioxidant enzymes activity in zebrafish (*Danio rerio*)

Hamed E.¹, Khajeh-Rahimi A.E.^{2*}; Kazempoor R.^{2*}, Nowruzi B.³

¹ Department of Science and Research, Faculty of Specialized Veterinary Sciences, Islamic Azad University, Tehran, Iran

² Department of Aquatic Animal Health and Disease, Faculty of Science and Research, Islamic Azad University, Tehran, Iran

³ Department of Biotechnology, Faculty of Converging Sciences and Technologies, Islamic Azad University, Science and Research Branch, Tehran, Iran

*Correspondence: AKR12783@gmail.com; rkbs_kh@yahoo.com

Keywords

Cyanobacteria,
Cyanotoxin,
Zebrafish,
Oxidative stress,
Histopathology,
Toxicology

Abstract

Cyanobacteria, ancient photosynthetic prokaryotes, form harmful blooms that degrade water quality and pose many risks to human health. The main objective of this study is to identify toxic cyanobacteria present in fish ponds, evaluate their effects on Zebrafish (*Danio rerio*) tissue, and investigate their characteristics. Samples were collected from the walls and floors of rainbow trout raceway ponds at Alborz Caspian Company, situated in Alborz province, Iran. The purpose of this collection was to isolate and examine cyanobacteria colonies. As a result of meticulous microscopic and macroscopic observations, three pure samples of *Calothrix* sp., *Nostoc* sp., and *Microcystis* sp. species were successfully identified. These samples were then transported to the laboratory and processed using the Z8 solid culture medium within a growth chamber. Cyanobacteria were identified based on their morphology using a light microscope and validated identification keys. The DNA extraction was performed using the cetyl-trimethyl-ammonium bromide method. Zebrafish were acclimated and fed with fish food containing lyophilized cyanobacteria for a period of 30 days. At specific intervals, fish were collected for histopathological analysis and measurement of antioxidant enzyme activity. The histopathological examination of intestinal tissue in the treatment groups exposed to lyophilized cyanobacteria revealed lesions including hyperplasia of enterocytes, reduction in their length, vacuolation of enterocytes, hyperplasia of goblet cells, and infiltration of lymphocytes. The gill samples from the treatment group exhibited severe histopathological abnormalities such as displacement of epithelial cells, fusion of lamellae, epithelial necrosis, and lymphocyte infiltration. These symptoms diminished over time. Hepatocellular lipid changes and vacuolation were observed in the treatment group's liver samples, peaking on the 30th day. The activity of superoxide dismutase (SOD) enzyme significantly increased in the exposed Zebrafish on the 30th day compared to the control group, and similar significant increases were observed on the 20th and 30th days ($p < 0.05$). There were no significant differences in Catalase (CAT) activity between the control and treatment groups ($p > 0.05$). Generally, the study identified specific histopathological abnormalities in the fish exposed to lyophilized cyanobacteria and observed changes in antioxidant enzymes activity. These findings contribute to understanding the impact of cyanobacteria on fish health status.

Article info

Received: January 2023

Accepted: November 2023

Published: March 2024



Copyright: © 2023 by the authors. Licensee MDPI, Basel, Switzerland. This article is an open access article distributed under the terms and conditions of the Creative Commons Attribution (CC BY) license (<https://creativecommons.org/licenses/by/4.0/>).

Introduction

Cyanobacteria, which are photosynthetic prokaryotes with Gram-negative characteristics, inhabit a wide range of aquatic and terrestrial environments. These organisms have a long evolutionary history that dates back to the Precambrian era. The ancient lineage of cyanobacteria contributes to the significant morphological variations observed among the numerous species, leading to challenges in their classification (Nawaz *et al.*, 2023). The reproduction of cyanobacteria is influenced by various factors, including light availability, water temperature, and nutrient availability, particularly nitrogen and phosphate. When these conditions are favorable, cyanobacteria can rapidly multiply and form blooms by aggregating together (Thawabteh *et al.*, 2023). Cyanobacterial blooms pose a significant threat to plants, animals, and human health. They deteriorate water quality and reduce dissolved oxygen levels, leading to damage to the gills of aquatic animals. Additionally, cyanobacteria produce toxic metabolites that can harm aquatic organisms, resulting in reduced growth, increased food conversion ratio, lower meat quality, economic losses, stress, and damage to breeding populations. Moreover, cyanobacterial toxins can accumulate in aquatic tissues and transfer through the food chain to higher trophic levels. Considering the expansion of industrial agriculture and the impact of climate change, the issue of increased cyanobacterial reproduction and global expansion has become a significant concern

for human health and well-being (Reisoglu and Aydin, 2023).

Cyanotoxins, which can periodically reappear in aquatic environments, pose a hazard to humans, animals, and aquatic organisms. There is a potential for chronic exposure to cyanotoxins at relatively low doses. Depending on the concentration of cyanotoxins in the water, they can cause severe poisoning, lead to the development of chronic diseases like cancer, and even result in death. From the perspectives of ecotoxicology, toxicology, and environmental chemistry, cyanotoxins represent an important group of chemical compounds. Cyanotoxins can be classified based on two main criteria. Firstly, their action mechanism in terrestrial vertebrates, particularly mammals, categorizes them into three primary classes: hepatotoxins, neurotoxins, and dermatotoxins. Secondly, their chemical structure allows for further classification into cyclic peptides, alkaloids, or lipopolysaccharides (LPS) (Nowruzi and Porzani, 2021).

Danio rerio, commonly known as Zebrafish, is a small bony fish frequently utilized as an animal model in toxicology experiments and risk assessments for various toxins and new drugs due to its short life cycle and significant similarities with humans (Galicioli *et al.*, 2023). The presence of cyanobacterial toxins in fish ponds has resulted in numerous challenges concerning the health of fish consumers, often leading to the temporary closure of these habitats. These toxins possess water solubility and are resistant to destruction by boiling water, further complicating their management. The production of toxins by

cyanobacterial strains exhibits substantial variability in response to environmental conditions. Consequently, toxins derived from cyanobacterial strains not only pose a significant concern for drinking water quality but also present considerable risks to the health of humans and animals when consuming contaminated fish. Among the secondary metabolites produced by cyanobacteria, microcystins have garnered extensive attention due to their significant presence and isotoxicity to humans and domestic animals.

Extensive research has been conducted to investigate the causes of poisoning in rice fields and various lakes in Iran. However, none of these studies have focused on the examination of cyanotoxins in fish ponds and their potential impact on fish tissue. Fish ponds, characterized by abundant food sources, provide an optimal environment for the growth and proliferation of cyanobacteria. During the hot seasons of the year, excessive cyanobacterial growth can result in the formation of green layers on the pond walls. The presence of toxic cyanobacteria cells in the water of fish breeding ponds, which are rich in nutrients, can lead to their growth and proliferation within the ponds. This issue not only poses a significant concern for the quality of drinking water but also presents a substantial risk to human health through the consumption of contaminated fish. Therefore, the objective of this study is to conduct the first-ever investigation into the morphological and molecular identification of toxic cyanobacteria in fish breeding ponds and their impact on fish tissue.

Material and methods

The sampling process involved collecting samples from the walls and floors of rainbow trout raceway ponds at Alborz Caspian Company, located in Alborz province, Iran. Three samples were obtained from each pool by scraping the walls using a spatula, and two samples were collected from the water using plastic bottles. These samples were then transported to the laboratory and placed in the Z8 solid culture medium within a growth chamber. The growth chamber maintained a constant temperature of $28\pm 2^{\circ}\text{C}$ and provided continuous fluorescent light with an intensity of 300 microns (Burgos *et al.*, 2018). Subsequently, the collected samples underwent successive cultures, separation, and purification processes, as described by Sun *et al.* (2023). Identification of the cyanobacteria was conducted based on their morphological characteristics using a light microscope equipped with a calibrated eyepiece. For accurate identification, valid identification keys provided by Drummond (2023) were utilized.

The Z8 culture medium was prepared by pouring 500 mL of distilled water into a 1000 mL Erlenmeyer flask. Subsequently, 10 ml each of stock solution number one, solution number two, and solution number three, along with 1 mL of solution number four, were added to a separate container. The volume was adjusted to one liter using distilled water. The pH of the solution was measured using a pH meter, and 10 grams of agar were added to create a solid culture medium. Finally, the medium was autoclaved at 121°C for 15 minutes. After cooling under a laminar hood, the medium

was poured into sterile Petri dishes and allowed to solidify (Łukaszewicz *et al.*, 2023). For purification, the strains were cultivated on agar pellets under sterile conditions using a light microscope and a needle loupe. Samples cultured in a liquid medium were transferred to a new liquid medium every two months and collected after six months. Subsequently, they were subjected to lyophilization by freezing in a Christ freeze dryer.

DNA extraction

The genetic material of the desired strains was extracted using the conventional cetyltrimethyl-ammonium bromide (CTAB) method. The method involved the use of CTAB solution (2% w/v), NaCl solution (1.4 M), EDTA solution (20 mM), and Rees-HCl solution (100 mM) with a pH of 8. To initiate the extraction process, 10 mg of the colony was taken from the plate and mixed with 800 μ L of lysis buffer. The mixture was then subjected to a hot water bath at 60°C for 30 minutes. Following this, chloroform was added to the solution and subsequently centrifuged for 10 minutes at room temperature (5000 \times g) (Pineda-Rodriguez *et al.*, 2023).

600 μ L of the upper phase was transferred to a new vial, and an equal volume of 100% isopropanol was added and thoroughly mixed. The mixture was then centrifuged for 10 minutes at 25°C with a speed of 10000 \times g. The upper phase was discarded, and to the DNA pellet, 500 μ L of 70% ethanol was added. This mixture was then centrifuged for another 10 minutes at 25°C with a speed of 5000 \times g. After discarding the upper phase, the DNA precipitate was partially dried for 10 minutes, followed by the addition of 50 μ L of autoclaved double-distilled water. For the subsequent reactions, a DNA template of 10-20 μ g, 0.5 μ M of each primer, 1.5 mM MgCl₂, 200 μ M dNTPs, 1U/ μ L Taq DNA polymerase (Invitrogen, Carlsbad, CA, USA), and ultrapure water were combined to reach a final volume of 25 μ L. The thermocycler was programmed according to the parameters specified in Table 1. After completion, all PCR products were visualized by electrophoresis on 1% agarose gels (SeaPlaque® GTG, Cambrex Corporation) following standard protocols and recorded. Additionally, SYBR® Gold Nucleic Acid Gel Stain (Invitrogen, Carlsbad, CA, EUA) was used to enhance visualization.

Table 1: PCR Program and Oligonucleotide Primers Used in This Study.

Target gene	Primers with their sequences (5'-3')	PCR condition	Reference
16S rRNA	PA (5'-AGAGTTTGATCCTGGCTCAG-3')	94°C, 3 min	(Lefler <i>et al.</i> , 2023)
	B23S (5'-CTTCGCCTCTGTGCTAGGT-3')	30 \times (94°C, 30 s; 55°C, 40 s; 72°C, 1.30 min)	
		72°C, 3 min	
		4°C, Continuous	

Fish maintenance

A total of 100 healthy Zebrafish specimens, with an average weight of 0.5 grams, were procured from the ornamental fish breeding

center for the purpose of conducting this experiment. These fish were divided into two groups of 50 each, namely the control group and the treatment group, 20 days

prior to the commencement of the study. Both groups were then transferred to separate 30-liter aquariums, maintained at a temperature of 25°C, to acclimate to the test environment. Throughout this acclimation period, the fish were provided with Biomar commercial dry food twice a day, and the lighting cycle was set to 12 h of light and 12 hours of darkness.

Following 20 days, the fish in the treatment group were provided with fish food mixed with 6 grams of lyophilized cyanobacteria, and this administration continued for a duration of 30 days. In the subsequent stage, 15 fish were randomly selected from each group on days 10, 20, and 30. Three fish from each group were preserved in 10% formalin for histopathological investigations during each collection, while the remaining fish were stored at -80°C in a freezer to measure antioxidant enzyme levels at the end of the study period. The total protein level of the tissues was measured using Bradford's method (1976). The amount of Glutathione peroxidase enzyme was tested using Glutathione peroxidase (GPx) assay kits (Lefler *et al.*, 2023). The activity of the Superoxide dismutase (SOD) enzyme was measured using the Flohe (1984) method. This method is based on measuring the

reduction of cytochrome C by Superoxide anion using the xanthine-xanthine oxidase system as a source of Superoxide radicals at a wavelength of 550 nm. The Catalase (CAT) enzyme activity was measured using the Aebi (1974) method, which involves the decrease in the concentration of H₂O₂ at a wavelength of 240 nm.

Data analysis

Intergroup changes in this study were assessed using one-way ANOVA followed by Tukey's post hoc test. Data analysis was performed using SPSS20 software, and figures were generated using Excel software.

Results

Results of isolation and purification of cyanobacterial samples from Alborz Caspian fish farm

The study began with the collection of samples from the water and walls of fish breeding ponds to isolate and examine individual colonies, focusing on their morphology. Subsequent cultures were conducted, and slides were prepared for microscopic and macroscopic observation to confirm the purity of the isolates. Ultimately, three pure samples of *Calothrix* sp., *Nostoc* sp., and *Microcystis* sp. species were obtained (Figs. 1 to 3).




Figure 1: Images of solid culture (left) and microscopic image (right) of *Microcystis* sp. (400× magnification).




Figure 2: Images of solid culture (left) and microscopic image (right) of *Nostoc* sp. (400× magnification).

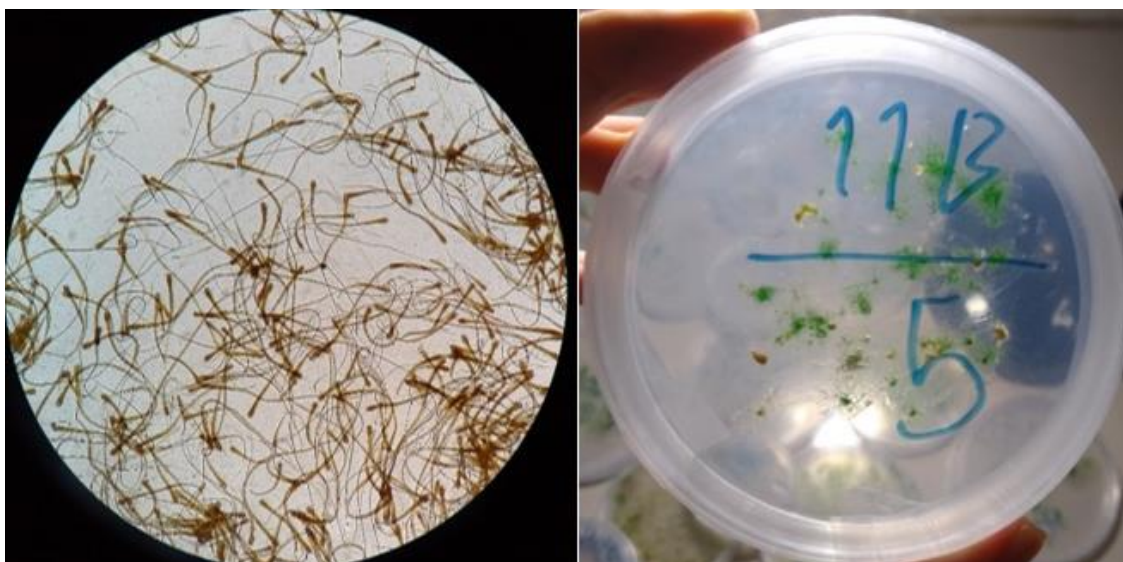

Figure 3: Solid culture (Left) and microscopic (Right) images of *Calothrix* sp. (400× magnification).

Histopathological observations

The histological examination of intestinal tissue samples from control groups 1, 2, and 3 revealed normal villi and enterocytes, without any discernible histopathological abnormalities. In contrast, the treatment groups exposed to lyophilized cyanobacteria exhibited notable lesions, including hyperplasia of enterocytes, reduction in their length, mild vacuolation of enterocytes, hyperplasia of goblet cells, and infiltration of lymphocytes from the submucosa to the mucosa. These lesions began to appear on the 10th day and

reached their maximum severity by the 30th day (Fig. 4).

The gill samples obtained from the control group on days 10, 20, and 30 exhibited normal conditions without any specific lesions. However, in the treatment group, severe histopathological abnormalities were observed on the 10th day, including displacement of epithelial cells, fusion of primary and secondary lamellae, mild epithelial necrosis, and infiltration of lymphocytes beneath the mucosa of the primary lamella.

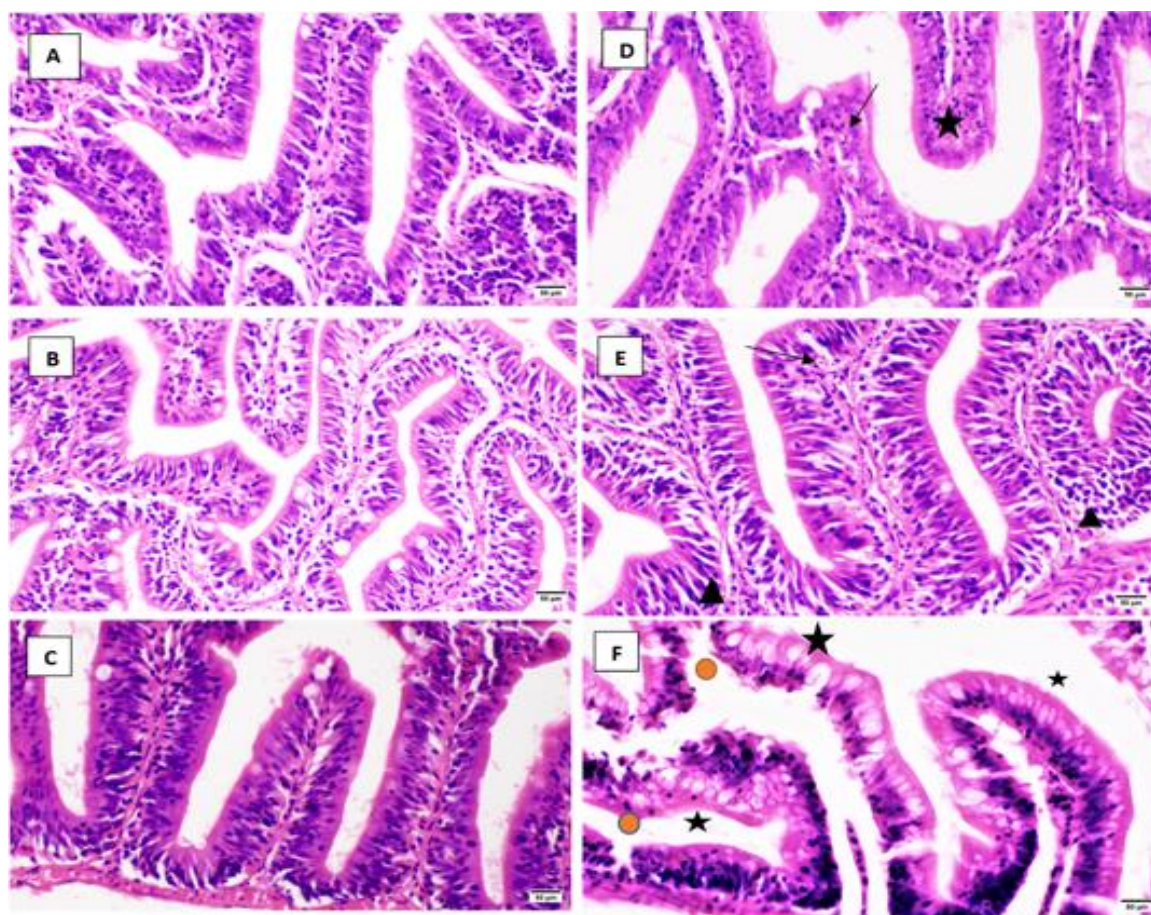


Figure 4: Histopathological lesions of the Zebrafish intestine (Hematoxylin and Eosin Staining; 400× magnification). (A) Day 10, Control (Normal Tissue). (B) Day 20, Control (Normal Tissue). (C) Day 30, Control (Normal Tissue). (D) Treatment: Fed with Lyophilized Cyanobacteria on Day 10 (Star: Epithelium Shortening, Hyperplasia of Enterocytes - Black Arrow: Vacuolation of Enterocyte). (E) Treatment: Fed with Lyophilized Cyanobacteria on the 20th Day (Triangle: Limited Infiltration of Lymphocytes into the Mucosa, Black Arrow: Vacuolation of Cytoplasm). (F) Treatment: Fed with Lyophilized Cyanobacteria on Day 30 (Circle: Enterocyte Necrosis, Infiltration of Lymphocytes into the Mucosa, Star: Abundant Mucus Production and Severe Hyperplasia of Goblet Cells).

By the 20th day of treatment, these symptoms had diminished, and on the 30th day, the fusion had completely resolved, with only scattered epithelial necrosis and hyperplasia of chloride cells observed (Fig. 5).

No specific lesions were observed in the samples isolated from the control group on days 10, 20, and 30. However, in the treatment group exposed to lyophilized cyanobacteria, hepatocellular lipid changes were observed, initiating transiently on the

tenth day, along with hepatocyte vacuolation. These symptoms progressed over time and reached their peak on the 30th day (Fig. 6).

Study of antioxidant enzymes

The assessment of Zebrafish SOD enzyme showed no significant difference in activity levels between the control and treatment groups on the 10th and 20th days ($p>0.05$).

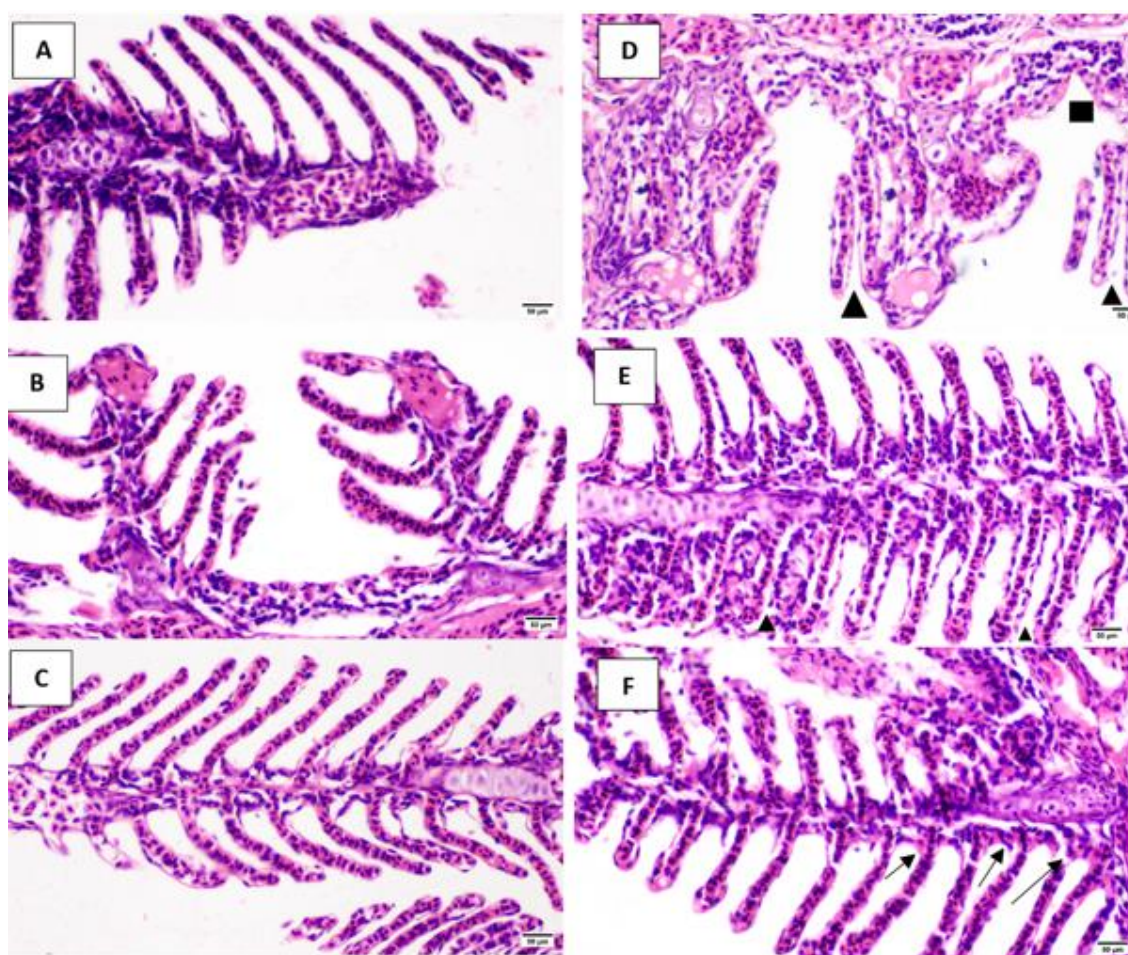


Figure 5: Histopathological lesions of Zebrafish gills (Hematoxylin and Eosin Staining; 400× Magnification). (A) Day 10, Control (Normal Tissue). (B) Day 20, Control (Normal Tissue). (C) Day 30, Control (Normal Tissue). (D) Treatment: Fed with Lyophilized Cyanobacteria on Day 10 (Triangle: Fusion of Primary and Secondary Blade, Epithelial Cell Migration, Square: Epithelial Necrosis). (E) Mild Inflammation (Triangle: Scattered Epithelial Necrosis). (F) Treatment: Fed with Lyophilized Cyanobacteria on Day 30 (Black Arrow: Chloride Cell Hyperplasia).

However, on the 30th day, there was a significant increase in the activity level of this enzyme in the treatment group ($p<0.05$) (Fig. 7).

The findings from the evaluation of Zebrafish SOD enzyme indicated that there was no significant difference in enzyme activity between the control and treatment groups on the 10th day ($p>0.05$). However, on the 20th day, there was a significant increase in enzyme activity in the treatment group ($p<0.05$). From the 20th to the 30th day, the enzyme activity remained relatively stable in the control group,

whereas a significant increase was observed in the treatment group ($p<0.05$) (Fig. 8).

The comparison of Catalase activity levels between the control and treatment groups did not reveal any significant differences on any of the assessed days. Over the course of one month, the activity of this enzyme remained relatively stable in the treatment group. However, in the control group, a notable decrease in Catalase activity was observed on the 30th day compared to the 10th day (Fig. 9).

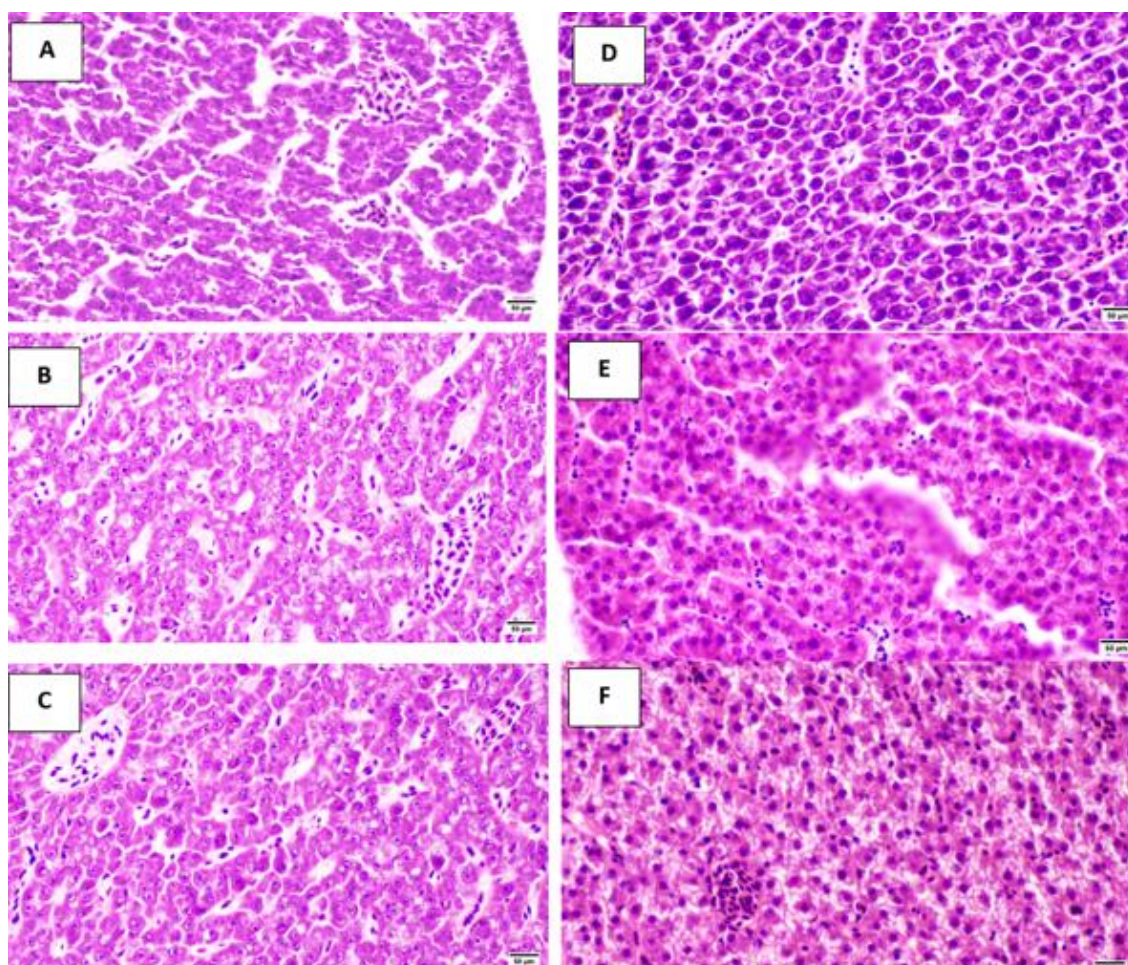


Figure 6: Histopathological lesions in Zebrafish liver (Hematoxylin and Eosin Staining; 400× Magnification). (A) Day 10, Control (Normal Tissue). (B) Day 20, Control (Normal Tissue). (C) Day 30, Control (Normal Tissue). (D) Treatment: Fed with Lyophilized Cyanobacteria on Day 10 (Mild Vacuolation of Hepatocytes). (E) Vacuolation of Hepatocytes and Fat Change. (F) Vacuolation of Hepatocytes and Fat Change.

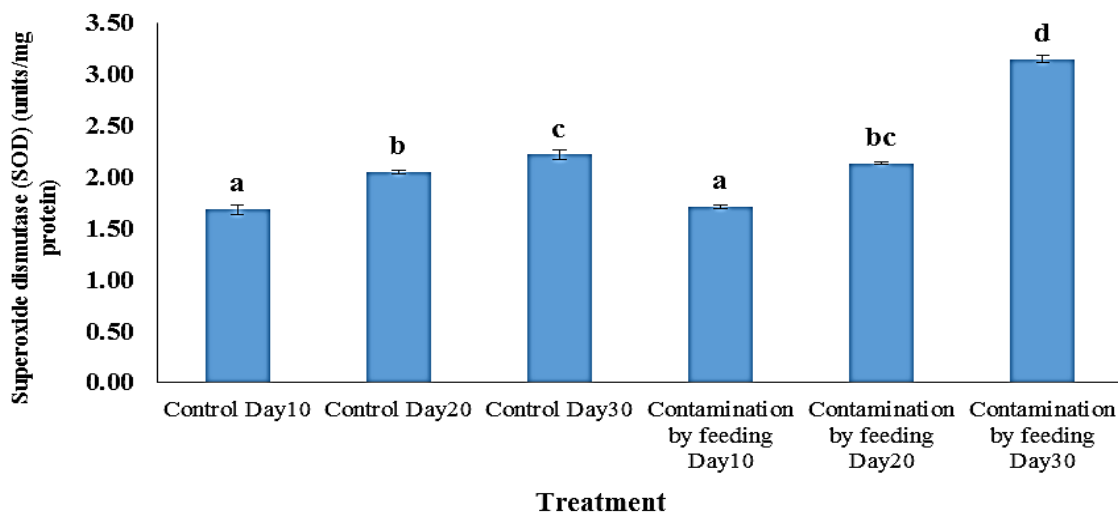


Figure 7: Superoxide dismutase activity (SOD) in Zebrafish on days 10, 20, and 30. Different letters indicate significant differences at the level of 0.05 in different groups.

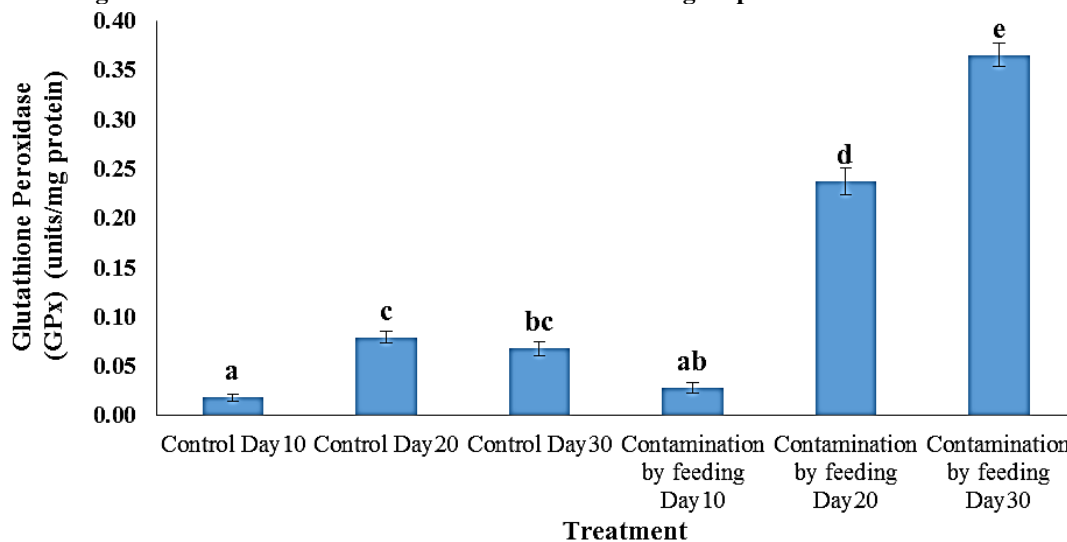


Figure 8: Glutathione peroxidase activity (GPx) in Zebrafish on days 10, 20, and 30. Different letters indicate a significant difference at the 0.05 level in different groups.

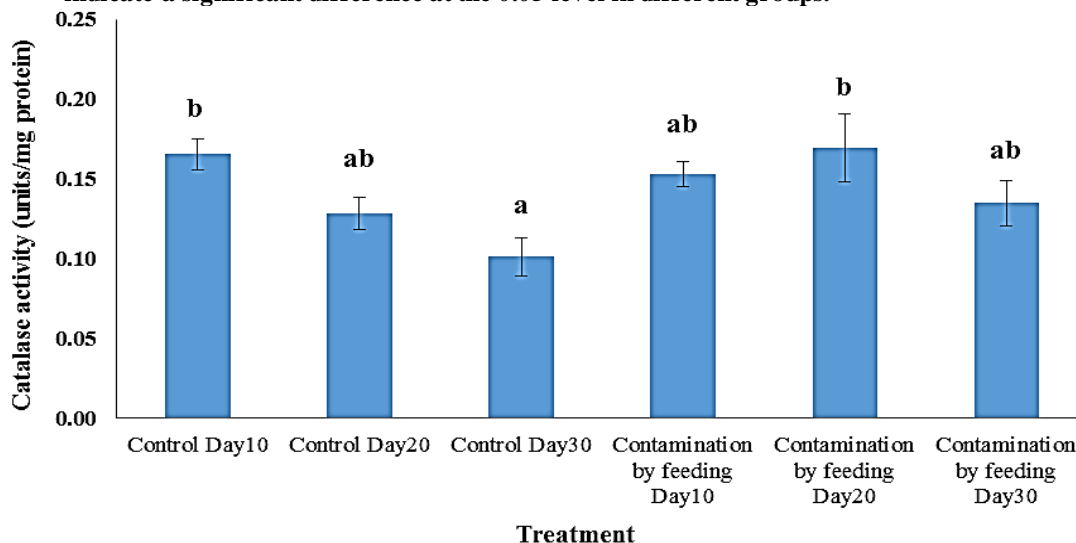


Figure 9: Catalase activity (CAT) in Zebrafish on days 10, 20, and 30. Different letters indicate significant differences at the 0.05 level in different groups.

Discussion

Cyanobacteria are known to produce a wide range of secondary metabolites, including both cyanobacterial toxins and compounds with potential therapeutic applications. In the present study, histopathological examination of the gills in treatment group 1 revealed the presence of lesions. Dysplasia and hyperplasia of the epithelium are non-specific defense mechanisms exhibited by fish to reduce the contact surface area of the gills with toxic and pollutant substances. However, these changes can impair the efficiency of gill function in gas exchange and potentially lead to suffocation in fish (Jenkins *et al.*, 2023).

On the 20th day, group 2 exhibited slight necrosis in the epithelium of the secondary lamellae; however, there was an improvement in the adhesion of the secondary lamellae, and no signs of inflammation were observed. This recovery can be attributed to the fish's adaptation to the new environmental conditions. In the gills of the third group, diffuse necrosis of the epithelium was observed, accompanied by transient inflammation and hyperplasia of chloride cells. The presence of Microcystin can disrupt the normal functioning of this organ by inhibiting gill ion pumps and causing an imbalance in ion exchange. The swelling and hyperplasia of chloride cells are defense responses of the gills to counteract this condition (Chen *et al.*, 2023). Kopp *et al.* (2018) conducted a study examining the oxidative stress response of rainbow trout to various stressors, including cyanobacterial biomass and arsenic metal. They emphasized the significant role of the antioxidant system in

responding to stress and protecting body tissues against these harmful factors. Paulino *et al.* (2017) investigated the acute and chronic effects of the crude extract of the R28 strain of cyanobacterium *Radiocystis fernandoi* on the protein phosphatase enzyme and liver structure of *Hoplias malabaricus* fish. Palikova *et al.* (2021) examined the impact of the cyanobacterium *Microcystis aeruginosa* on the severity of spring viral disease in carp. The study indicated that the combination of exposure to carp spring viremia virus and cyanobacteria as an environmental stressor led to changes in fish cholesterol and glucose levels, as well as increased activity of alanine aminotransferase. The study concluded that the simultaneous presence of disease and cyanobacteria worsened the indicators related to immune system function and liver health. Drobac Backović *et al.* (2021) conducted a study in Serbia, sampling water and fish from 13 common carp (*Cyprinus carpio*) breeding ponds, and identified the presence of saxitoxin, nodularin, and microcystin toxins. Histopathological examinations revealed damage to the liver, kidney, gills, and muscles of the fish, with the accumulation of toxins confirmed in the fish muscles.

Landsberg *et al.* (2020) discussed the factors contributing to the high mortality of fish in the Saint John River in Florida. It was suggested that the increased salinity of the water and the breakdown of the cyanobacterial bloom *Aphanizomenon* may have resulted in the release of cyanotoxins into the water. These toxins, combined with deteriorating water quality and the presence of other pathogens, were identified as the causes of fish mortality in the river. Prasuna

et al. (2021) conducted a study on the nutritional impact of the cyanobacterium *Anabaena* in the diet of *Pangasius sutchi*. The study revealed that this nitrogen-fixing cyanobacterium could serve as a viable and cost-effective food source, enhancing the physical characteristics of the fish such as color, length, and body weight. Hardy *et al.* (2015) examined the accumulation of cyanotoxins in fish tissues from nine lakes in Washington State. Using ELISA and liquid chromatography, they quantified the levels of microcystin and similar compounds in fish tissue. The study found that microcystin accumulation was higher in the liver and intestines compared to other tissues, while the accumulation of these toxins in fish fillets was within acceptable limits. The study also recommended thorough cleaning of fish before consumption and the removal of entrails. In a study conducted by Al-Ali *et al.* (2011) on grass carp over 15 days, histopathological changes were observed in the gill tissue after feeding the fish with the cyanobacterium *Nostoc muscurum*. Within 24 hours of feeding, hyperplasia of epithelial cells, adhesion of secondary lamellae to lamellae, and congestion of vessels were observed. These changes persisted until the 15th day, with the additional occurrence of hyperplasia in the secondary lamellae and, in some areas, separation of the epithelial layer from the secondary lamellae. Drobac *et al.* (2016) investigated 13 carp breeding ponds in Serbia that experienced cyanobacterial blooms. Their findings revealed epithelial hyperplasia, lamella fusion, as well as hyperplasia and hypertrophy of chloride cells in the gills. Similarly, García-

Mendoza *et al.* (2018) reported hyperplasia of epithelial cells, detachment of the epithelium, bleeding and tearing of lamellae, and fusion of secondary lamellae.

Exposure to microcystin has been demonstrated to have various effects on fish, including impacting growth rate and osmoregulation, increasing liver enzyme activities in the serum and heart rate, altering behavior, and causing histopathological effects in organs such as the liver, intestine, kidneys, heart, spleen, or gills. However, the extent of these effects depends on the route of exposure. Fish can come into contact with these toxins either through ingestion, particularly for species that primarily feed on phytoplankton, or passively when the toxins are absorbed through the gills during respiration. There have been reports of fish mortality occurring in ponds and lakes following the collapse of toxic cyanobacterial blooms (Yu *et al.*, 2023).

The inhibition of phosphatase 1 and phosphatase A2 enzymes by hepatotoxins, such as microcystin, appears to disrupt the function and cellular structure of hepatocytes. This disruption leads to cellular swelling and increasing in liver volume and weight (Falfushynska *et al.*, 2023). Studies on tilapia fish have reported changes in liver and gill protein after consuming toxic cyanobacteria over a period of 21 days (Veerabadhran *et al.*, 2023). Furthermore, the injection of pure microcystin in silver carp was found to significantly decrease liver protein levels (Zhang *et al.*, 2022). The rounding of hepatocytes, a consequence of disrupted cellular structure, has also been observed as an effect of hepatotoxins in other studies

(Qiao *et al.*, 2016; Azizova and Ubaydullayeva, 2023). Generally, these cellular damages result in abnormalities in hepatocyte metabolism, particularly affecting glycogen synthesis. Two enzymes, glycogen synthetase and glycogen phosphorylase, play a role in controlling glycogen synthesis in the liver. Microcystin's impact increases the activity of the liver glycogen phosphorylase enzyme, leading to an elevation in the process of glycogen breakdown. The combination of increased energy demands for fish to maintain homeostasis in challenging environments, aid in detoxification, and facilitate tissue repair, leads to a substantial reduction in glycogen levels in hepatocytes. This decrease is commonly observed as a histopathological symptom (Macirella *et al.*, 2016; Qiao *et al.*, 2016).

In this study, no instances of hepatocyte necrosis or extensive deformation were observed. However, vacuolation of hepatocytes and fat changes were observed starting from the 10th day, and the intensity of these changes increased as the duration of the test increased. Vacuoles present in the cytoplasm of liver cells can contain lipids and glycogen, which are associated with the normal metabolic function of the liver. A decrease in glycogen content within liver cells is typically observed in animals experiencing stress. The increased energy demand to respond to stress leads to a reduction in glycogen and lipid levels in hepatocytes, resulting in vacuolation in the cytoplasm. Furthermore, vacuolation may indicate an imbalance between the rate of substance synthesis in liver parenchymal cells and the rate of diffusion of these

substances in the systemic circulation. This imbalance can cause cellular enlargement and, in some cases, rupture of the cell membrane, ultimately resulting in necrosis.

Fish that consume cyanobacteria as part of their diet experience significant effects on their intestines due to the presence of cyanotoxins. These cyanotoxins enter the intestine through the ingestion of cyanobacteria, are absorbed into the bloodstream, and eventually reach the liver. Within the liver, a portion of the cyanotoxins enters the bloodstream to be eliminated through the kidneys and gills. The remaining toxins are transported back to the intestine through the bile. Histopathological changes commonly observed in the intestine include adhesion of the small intestine villi, hyperplasia of epithelial cells, and hyperplasia of goblet cells. These changes are accompanied by non-specific defense reactions of the body to cyanotoxins, aimed at reducing the severity of toxin-induced damage. These defense mechanisms involve reducing the contact surface and increasing mucus production. Intestinal injuries can have adverse effects on food absorption, leading to malnutrition, reduced growth rates, and negative impacts on fish reproduction. Additional histopathological lesions in the intestine include edematous changes, infiltration of lymphocytes into the mucosa and submucosa, thickening of the lamina propria, necrosis of epithelial cells with pyknosis of the nucleus, and cell lysis. Occasionally, mucoid degeneration occurs as a result of the cytotoxic effects of cyanotoxins, causing deformation of intestinal goblet cells and a loss of their

ability to secrete mucus (Drobac *et al.*, 2016).

The results revealed that the consumption of a diet containing lyophilized cyanobacteria led to significant histopathological changes in the intestine. In the first group (10th day), mild degrees of toxic damage were observed, characterized by vacuolation and hyperplasia of enterocytes, as well as a reduction in the length of enterocytes. The second group (20th day) exhibited increased vacuolation in enterocyte cytoplasm, limited penetration of leukocytes into the mucosa, and epithelial necrosis. In the third group (30th day), more severe histopathological changes were observed, including enterocyte necrosis, mild to moderate infiltration of lymphocytes from the submucosa to the mucosa, hyperplasia of goblet cells, and abundant production of mucus. These findings help explain the presence of hanging feces in the fish.

No histological abnormalities in the kidney were found in comparison to the control group in this study. The variations in the occurrence of histopathological lesions can be attributed to differences in the susceptibility of various fish species to toxins, the diverse responses exhibited by fish when exposed to toxins through different routes such as intraperitoneal injection or dietary ingestion, and the distinct mechanisms through which different types of microcystin induce illness in fish. It is widely believed that the hydrophilic or hydrophobic nature of microcystin may lead to heterogeneous distribution of the toxin in the body at different levels of toxicity in various organs (Wang *et al.*, 2022). For example, RR

microcystin, which is more hydrophilic than LR, is more readily absorbed by the kidney and has a greater ability to increase kidney acid phosphatase activity compared to liver acid phosphatase. In tilapia fish, it has been observed that intraperitoneal injection of microcystin leads to glomerulopathy and an increase in renal acid phosphatase (Beasley *et al.*, 2023). Interstitial tissue congestion and edema have been associated with decreased protein levels and increased kidney volume (Palmer and Clegg, 2023). However, the reduction in kidney protein levels was not observed in the research conducted by Ko *et al.* (2020). Degenerative lesions in the tubule, glomerulus, and interstitial tissue of carp kidneys have been observed, which aligns with the findings of Sula *et al.* (2020). Zhang *et al.* (2022) reported tubule necrosis and expansion of Bowman's capsule following microcystin injection in rainbow trout. On the other hand, no lesions were observed in common carp following the consumption of microcystin extract (Xu *et al.*, 2020).

In the present study, it was found that there was no significant alteration in the activity of the Superoxide dismutase (SOD) enzyme compared to the control group until the 20th day. However, a significant increase in SOD enzyme activity was observed on the 30th day. Furthermore, the activity of the Glutathione peroxidase (GPx) enzyme showed a notable increase compared to the control group, starting from the 20th day, and this increase persisted until the 30th day. Microcystin inhibits protein phosphatase enzymes, leading to protein transphosphorylation. This state can enhance the activity of

enzymes like GPx (Al-mammori *et al.*, 2019). Additionally, the increase in SOD enzyme activity can result in increased hydrogen peroxide production, which in turn increases the demand for GPx enzyme. These factors may explain the significant increase in GPx enzyme activity on the 20th and 30th days. However, the activity level of CAT enzyme did not show a significant change compared to the control group. This could be due to the sufficient increase in GPx enzyme activity, which allows the fish to adapt to environmental conditions and maintain control over hydrogen peroxide levels within cells. Alternatively, the inhibitory effect of the microcystin toxin may have prevented the increase in Catalase activity (Muhammad *et al.*, 2023).

In the study conducted by Martins *et al.* (2019), the impact of microcystin on trahira fish was examined. It was found that the activity of the liver Glutathione peroxidase enzyme significantly increased compared to the control group. However, no changes were observed in the levels of Superoxide dismutase and Catalase. Similarly, in the gills, there was a significant increase in the activity levels of Superoxide dismutase and Glutathione peroxidase enzymes, but no difference was found in gill Catalase activity compared to the control group. In silver carp, during a cyanobacterial bloom, the activities of antioxidant enzymes such as Catalase, Superoxide dismutase, Glutathione peroxidase, and Glutathione S-transferase exhibited temporary changes. These enzyme activities increased during the bloom and then decreased (Li *et al.*, 2023). It was concluded that fish antioxidant enzymes play a crucial role in protecting cells against oxidative stress

induced by microcystin. Similar findings were observed in the liver of loach fish (*Misgurnus mizolepis*) exposed to a low dose of microcystin, as well as in the liver, kidney, and gill of tilapia fish (*Oreochromis sp.*) fed a mixture of food and cyanobacteria for 21 days (Tibbetts *et al.*, 2023).

Sakuragui *et al.* (2019) conducted a study to examine the acute and sub-chronic effects of *Radiocystis fernandoi* cyanobacterial extract on the induction of anemia and oxidative stress in *Hoplias malabaricus*. Acute poisoning was investigated through intraperitoneal injection. The study found an increase in the levels of Glutathione s-transferase, Superoxide dismutase, and red blood cell Glutathione enzymes. However, despite this increase, oxidative stress persisted in the cells, leading to elevated DNA damage and lipid peroxidation. Abdel-Latif and Abou Khashaba (2017) investigated the subchronic toxicity of *Microcystis aeruginosa* in Nile tilapia using various routes of toxin exposure, including immersion, food, and intraperitoneal injection, over a period of three weeks. The study revealed a significant increase in the activity of Glutathione reductase, Glutathione peroxidase, and Catalase enzymes in the serum, kidney, and liver of fish exposed to the toxin through intraperitoneal injection or addition of the toxin to the food diet starting from the fourteenth day.

Aquatic cyanobacterial mats in active growth are likely to have minimal risk since the majority of cyanotoxins are contained within the cells and not released into the water. However, when these mats die, such

as when a paddy field is drained, there is a potential for a large-scale release of cyanotoxins. These findings suggest that aquatic cyanobacteria hold promise as an untapped natural resource, as they possess numerous bioactive compounds that could be valuable to the pharmaceutical industry. However, it is necessary to evaluate the toxicity of these aquatic cyanobacteria to soil microorganisms, which requires further and more comprehensive investigations. Additionally, it is recommended to conduct seasonal monitoring of cyanobacterial populations and the ratio of toxic-to-non-toxic strains in fish farms, as well as assess the concentration of toxins accumulated in the tissues of edible fish.

Conflicts of interest

The authors declare no conflicts of interest regarding the publication of this article.

References

- Abdel-Latif, H.M.R. and Abou Khashaba, A.M., 2017.** Subchronic toxicity of Nile tilapia with different exposure routes to *Microcystis aeruginosa*: Histopathology, liver functions, and oxidative stress biomarkers. *Veterinary World*, 10(8), 955-963.
DOI:10.14202/vetworld.2017.955-963
- Aebi, H., 1974.** Catalase. *Methods in Enzymatic Analysis*, 2, 671-678. DOI: 10.1016/b978-0-12-091302-2.50032-3
- Al-Ali, A.A., Al-Sultan, E.Y. and Al-Sultan, F.A., 2011.** Histopathological effects of toxic alga *Nostoc muscurum* on juvenile grass carp fish (*Ctenopharyngodon idella* Val. 1844). *Journal of Marsh Bulletin*, 6, 32-61.
- Al-mammori, A.M., Al-Amari, M.J. and Khadairi, M.M., 2019.** Study of purified microcystin-Lr toxicity on biochemical markers in blood and liver of *Cyprinus carpio* during acute exposure. *Plant Archives*, 19(2), 695-701.
- Azizova, F. and Ubaydullayeva, M., 2023.** Cytological picture of apoptosis in liver cells. *Universum: Medicine and Pharmacology*, 9(102), 10-13.
- Beasley, V., Carmichael, W., Haschek, W.M., Colegrove, K.M. and Solter, P., 2023.** Phycotoxins. In Haschek and Rousseaux's Handbook of Toxicologic Pathology, 3 (pp. 305-391). Academic Press. DOI:10.1016/B978-0-443-16153-7.00005-8
- Bradford, M.M., 1976.** A rapid and sensitive method for the quantitation of microgram quantities of protein utilizing the principle of protein-dye binding. *Analytical Biochemistry*, 72(1-2), 248-254. DOI:10.1016/0003-2697(76)90527-3
- Burgos, M.J.G., Romero, J.L., Pulido, R.P., Molinos, A.C., Gálvez, A. and Lucas, R., 2018.** Analysis of potential risks from the bacterial communities associated with air-contact surfaces from tilapia (*Oreochromis niloticus*) fish farming. *Environmental Research*, 160, 385-390.
DOI:10.1016/j.envres.2017.10.021
- Chen, X., Liu, S., Ding, Q., Teame, T., Yang, Y., Ran, C., Zhang, Z. and Zhou, Z., 2023.** Research advances in the structure, function, and regulation of the gill barrier in teleost fish. *Water Biology and Security*, 2(2), 100139. DOI:10.1016/j.watbs.2023.100139

- Drobac Backović, D., Tokodi, N., Marinović, Z., Lujić, J., Dulić, T., Simić, S.B., Đorđević, N.B., Kitanović, N., Šćekić, I., Urbányi, B. and Meriluoto, J., 2021.** Cyanobacteria, cyanotoxins, and their histopathological effects on fish tissues in Fehérvárcsurgó reservoir, Hungary. *Environmental Monitoring and Assessment*, 193(9), 554. DOI:10.1007/s10661-021-09324-3
- Drobac, D., Tokodi, N., Lujić, J., Marinović, Z., Subakov-Simić, G., Dulić, T., Važić, T., Nybom, S., Meriluoto, J., Codd, G.A. and Svirčev, Z., 2016.** Cyanobacteria and cyanotoxins in fishponds and their effects on fish tissue. *Harmful Algae*, 55, 66-76. DOI:10.1016/j.hal.2016.02.007
- Drummond, A., 2023.** A study of iron-oxidising bacteria, their habitats and their associated biogenic iron ochre, sampled from the Greater Glasgow area, Doctoral dissertation, University of Glasgow, Scotland. DOI:10.5525/gla.thesis.83400
- Falfushynska, H., Kasianchuk, N., Siemens, E., Henao, E. and Rzymiski, P., 2023.** A review of common cyanotoxins and their effects on fish. *Toxics*, 11(2), 118. DOI:10.3390/toxics11020118
- Flohe, L., 1984.** Superoxide dismutase assays. *Methods in Enzymology*, 105, 93-104. DOI:10.1016/S0076-6879(84)05013-8
- Galicioli, M.E.A., Silva, J.F., Prodocimo, M.M., Laureano, H.A., Calado, S.L.D.M., Oliveira, C.S. and Guiloski, I.C., 2023.** Toxicological Effects of Thimerosal and Aluminum in the Liver, Kidney, and Brain of Zebrafish (*Danio rerio*). *Metabolites*, 13(9), 975-991. DOI:10.3390/metabo13090975
- García-Mendoza, E., Cáceres-Martínez, J., Rivas, D., Fimbres-Martínez, M., Sánchez-Bravo, Y., Vásquez-Yeomans, R. and Medina-Elizalde, J., 2018.** Mass mortality of cultivated northern bluefin tuna *Thunnus thynnus orientalis* associated with *Chattonella* species in Baja California, Mexico. *Frontiers in Marine Science*, 454. DOI:10.3389/fmars.2018.00454
- Hardy, F.J., Johnson, A., Hamel, K. and Preece, E., 2015.** Cyanotoxin bioaccumulation in freshwater fish, Washington State, USA. *Environmental Monitoring and Assessment*, 187, 1-15. DOI: 10.1007/s10661-015-4875-x
- Jenkins, J.A., Musgrove, M. and White, S.J.O., 2023.** Outlining Potential Biomarkers of Exposure and Effect to Critical Minerals: Nutritionally Essential Trace Elements and the Rare Earth Elements. *Toxics*, 11(2), 188. DOI:10.3390/toxics11020188
- Ko, G.J., Rhee, C.M., Kalantar-Zadeh, K. and Joshi, S., 2020.** The effects of high-protein diets on kidney health and longevity. *Journal of the American Society of Nephrology: JASN*, 31(8), 1667. DOI: 10.1681/ASN.2020010028
- Kopp, R., Palíková, M., Papežiková, I., Mareš, J., Navrátil, S., Pikula, J. and Pohanka, M., 2018.** Oxidative stress response of rainbow trout (*Oncorhynchus mykiss*) to multiple stressors. *Acta Veterinaria Brno*, 87(1), 55-64. DOI:10.2754/avb201887010055

- Landsberg, J.H., Hendrickson, J., Tabuchi, M., Kiryu, Y., Williams, B.J. and Tomlinson, M.C., 2020.** A large-scale sustained fish kill in the St. Johns River, Florida: A complex consequence of cyanobacteria blooms. *Harmful Algae*, 92, 101771.
<https://doi.org/10.1016/j.hal.2020.101771>
- Lefler, F.W., Berthold, D.E. and Dail Laughinghouse IV, H., 2023.** CyanoSeq: a database of cyanobacterial 16S rRNA sequences with curated taxonomy. *Journal of Phycology*, 59(3), 470-480. DOI:10.1111/jpy.13335
- Li, J.J., Dai, M.J. and Xue, J.Z., 2023.** Investigation on toxicity and mechanism to *Daphnia magna* for 14 disinfection by-products: Enzyme activity and molecular docking. *Science of the Total Environment*, 905, 167059.
DOI:10.1016/j.scitotenv.2023.167059
- Łukaszewicz, P., Siudak, P., Kropidłowska, K., Caban, M. and Haliński, Ł.P., 2023.** Unicellular cyanobacteria degrade sulfoxaflo to its amide metabolite of potentially higher aquatic toxicity. *Chemosphere*, 337, 139440.
DOI:10.1016/j.chemosphere.2023.139440
- Macirella, R., Guardia, A., Pellegrino, D., Bernabò, I., Tronci, V., Ebbesson, L.O., Sesti, S., Tripepi, S. and Brunelli, E., 2016.** Effects of two sublethal concentrations of mercury chloride on the morphology and metallothionein activity in the liver of Zebrafish (*Danio rerio*). *International Journal of Molecular Sciences*, 17(3), 361.
DOI:10.3390/ijms17030361
- Martins, N.D., Yunes, J.S., McKenzie, D.J., Rantin, F.T., Kalinin, A.L. and Monteiro, D.A., 2019.** Microcystin-LR exposure causes cardiorespiratory impairments and tissue oxidative damage in trahira, *Hoplias malabaricus*. *Ecotoxicology and Environmental Safety*, 173, 436-443.
DOI:10.1016/j.ecoenv.2019.02.053
- Muhammad, F.S., Chia, M.A., Abolude, D.S., Tanimu, S. and Otogo, R.A., 2023.** Growth, antioxidant response and microcystin production by *Microcystis aeruginosa* exposed to the surfactant perfluorooctanesulfonic acid (PFOS). *Phycologia*, 62(3), 259-267.
DOI:10.1080/00318884.2023.2189408
- Nawaz, T., Gu, L., Fahad, S., Saud, S., Jiang, Z., Hassan, S. and Zhou, R., 2023.** A comprehensive review of the therapeutic potential of cyanobacterial marine bioactives: Unveiling the hidden treasures of the sea. *Food and Energy Security*, 12(5), e495.
DOI:10.1002/fes3.495
- Nowruzi, B. and Porzani, S.J., 2021.** Toxic compounds produced by cyanobacteria belonging to several species of the order Nostocales: A review. *Journal of Applied Toxicology*, 41(4), 510-548. DOI:10.1002/jat.4088
- Palikova, M., Kopp, R., Kohoutek, J., Blaha, L., Mares, J., Ondrackova, P., Papezikova, I., Minarova, H., Pojezdal, L. and Adamovsky, O., 2021.** Cyanobacteria *Microcystis aeruginosa* Contributes to the Severity of Fish Diseases: A Study on Spring Viraemia of Carp. *Toxins*, 13(9), 601.
DOI:10.3390/toxins13090601

- Palmer, B.F. and Clegg, D.J., 2023.** Kidney-protective effects of SGLT2 inhibitors. *Clinical Journal of the American Society of Nephrology*, 18(2), 279-289. DOI: 10.2215/CJN.09380822
- Paulino, M.G., Tavares, D., Bieczynski, F., Pedrão, P.G., Souza, N.E.S., Sakuragui, M.M., Luquet, C.M., Terezan, A.P., Fernandes, J.B., Giani, A. and Fernandes, M.N., 2017.** Crude extract of cyanobacteria (*Radiocystis fernandoi*, strain R28) induces liver impairments in fish. *Aquatic Toxicology*, 182, 91-101.
<https://doi.org/10.1016/j.aquatox.2016.11.012>
- Pineda-Rodriguez, Y.Y., Pompelli, M.F., Jarma-Orozco, A., Rodríguez, N.V. and Rodriguez-Paez, L.A., 2023.** A new and profitable protocol to DNA extraction in *Limnospira maxima*. *Methods and Protocols*, 6(4), 62.
DOI:10.3390/mps6040062
- Prasuna, R.G., Bandaru, A. and Bera, S., 2021.** Enhancement of Growth and Colour of *Pangasius Sutchi* with *Anabaena Variabilis* as Fish Feed. *Annals of the Romanian Society for Cell Biology*, 7694-7704.
- Qiao, Q., Le Manach, S., Huet, H., Duvernois-Berthet, E., Chaouch, S., Duval, C., Sotton, B., Ponger, L., Marie, A., Mathéron, L. and Lennon, S., 2016.** An integrated omic analysis of hepatic alteration in medaka fish chronically exposed to cyanotoxins with possible mechanisms of reproductive toxicity. *Environmental pollution*, 219, 119-131.
DOI:10.1016/j.envpol.2016.10.029
- Reisoglu, Ş. and Aydin, S., 2023.** Microalgae as a promising candidate for fighting climate change and biodiversity loss. IntechOpen.
DOI: 10.5772/intechopen.1002414
- Sakuragui, M.M., Paulino, M.G., e Souza, N.E.D.S., Tavares, D., Terezan, A.P., Pesenti, E., Giani, A., Fernandes, J.B., Cestari, M.M. and Fernandes, M.N., 2019.** Crude extract of cyanobacterium *Radiocystis fernandoi* strain R28 induces anemia and oxidative stress in fish erythrocytes. *Toxicon*, 169, 18-24. DOI:10.1007/978-3-031-34854-9_15
- Sula, E., Aliko, V., Marku, E., Nuro, A. and Faggio, C., 2020.** Evaluation of kidney histopathological alterations in Crucian Carp, *Carassius carassius*, from a pesticide and PCB-contaminated freshwater ecosystem, using light microscopy and organ index mathematical model. *International journal of aquatic biology*, 8(3), 154-165.
- Sun, J., Zhang, Z., Zhang, S., Dan, Y., Sun, H., Wu, Y., Luan, G. and Lu, X., 2023.** Engineering Cyanobacterial Cell Factories for Photosynthetic Production of Fructose. *ACS Synthetic Biology*, 12(10), 3008-3019.
DOI: 10.1021/acssynbio.3c00338
- Thawabteh, A.M., Naseef, H.A., Karaman, D., Bufo, S.A., Scrano, L. and Karaman, R., 2023.** Understanding the risks of diffusion of cyanobacteria toxins in rivers, lakes, and potable water. *Toxins*, 15(9), 582.
DOI:10.3390/toxins15090582
- Tibbetts, S.M., MacPherson, M.J., Park, K.C., Melanson, R.J. and Patelakis, S.J., 2023.** Composition and apparent digestibility coefficients of essential

- nutrients and energy of cyanobacterium meal produced from *Spirulina* (*Arthrospira platensis*) for freshwater-phase Atlantic salmon (*Salmo salar* L.) pre-smolts. *Algal Research*, 70, 103017. DOI:10.1016/j.algal.2023.103017
- Veerabadhran, M., Manivel, N., Sarvalingam, B., Seenivasan, B., Srinivasan, H., Davoodbasha, M. and Yang, F., 2023.** State-of-the-art review on the ecotoxicology, health hazards, and economic loss of the impact of microcystins and their ultrastructural cellular changes. *Aquatic Toxicology*, 256, 106417. <https://doi.org/10.1016/j.aquatox.2023.106417>
- Wang, M., Chen, J., Hu, L., Wei, Y., Liu, Y., Gao, P., Liu, C., Song, Y., Ding, N., Liu, X. and Wang, R., 2022.** Research progress and trends of bismuth-based photocatalytic materials in algae inhibition: A review. *Journal of Environmental Chemical Engineering*, 10(5), 108408. DOI:10.1016/j.jece.2022.108408
- Xu, S., Yi, X., Liu, W., Zhang, C., Massey, I.Y., Yang, F. and Tian, L., 2020.** A review of nephrotoxicity of microcystins. *Toxins*, 12(11), 693. DOI:10.3390/toxins12110693
- Yu, S., Xu, C., Tang, T., Zhang, Y., Effiong, K., Hu, J., Bi, Y. and Xiao, X., 2023.** Down-regulation of iron/zinc ion transport and toxin synthesis in *Microcystis aeruginosa* exposed to 5, 4'-dihydroxyflavone. *Journal of Hazardous Materials*, 460, 132396. DOI:10.1016/j.jhazmat.2023.132396
- Zhang, D., Yuan, L., Zhang, L., Qiu, T., Liao, Q., Xiang, J., Luo, L. and Xiong, X., 2022.** Pathological and biochemical characterizations of microcystin-LR-induced liver and kidney damage in chickens after acute exposure. *Toxicon*, 220, 106952. DOI:10.1016/j.toxicon.2022.106952